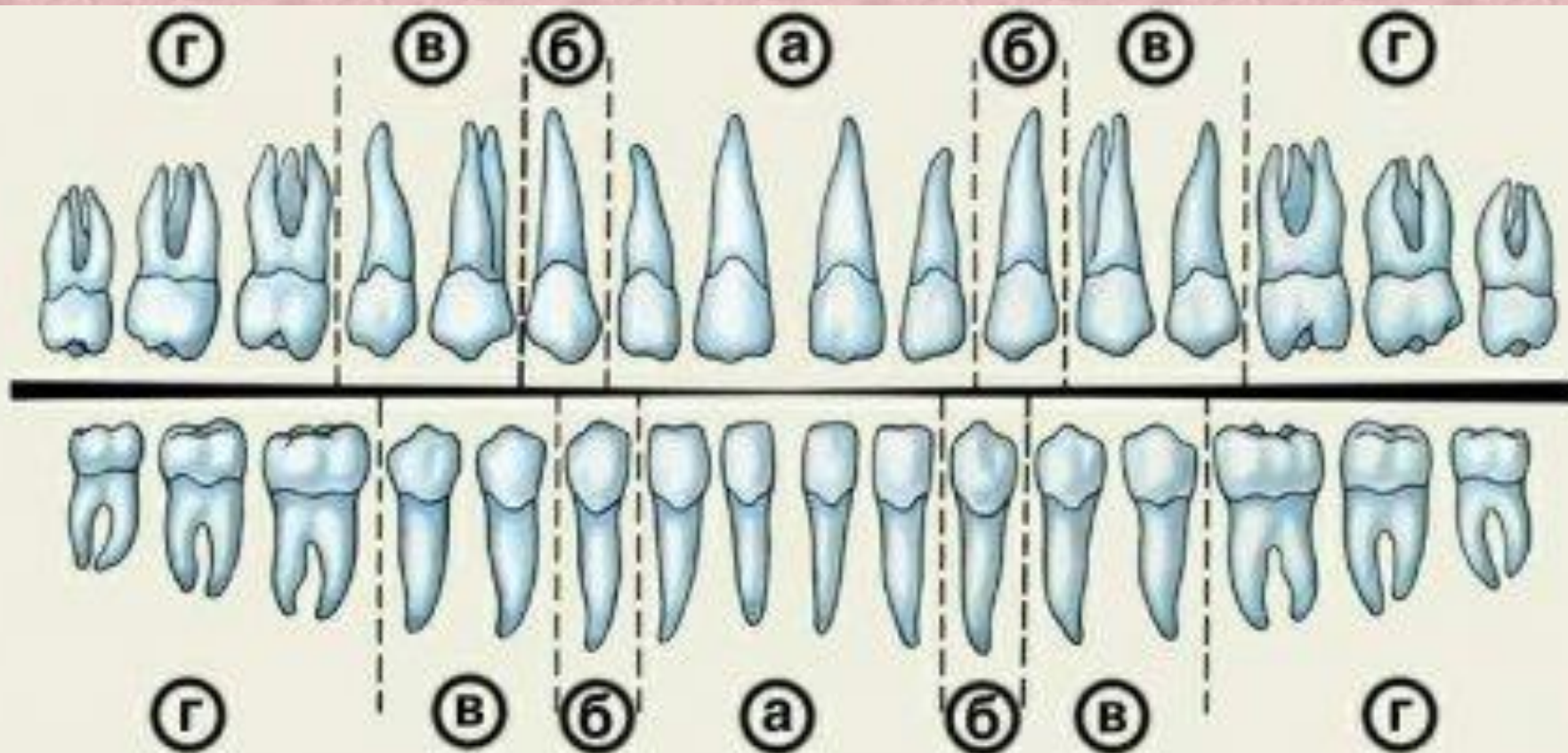




Structure and function of the teeth.

Dental hygiene

Yamchikova Dasha

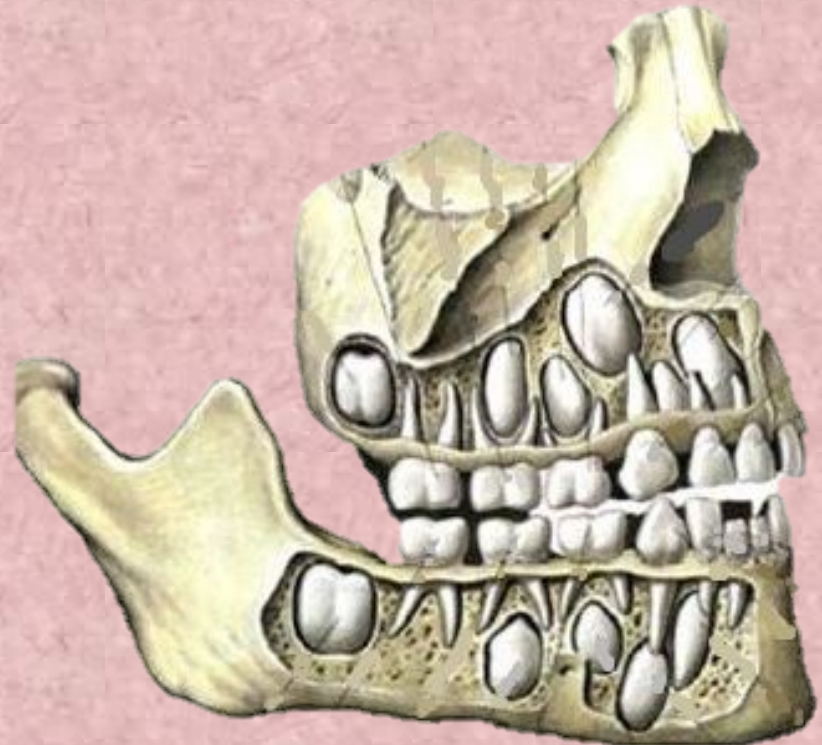

Incisors and canines for biting food; small and large molars for grinding, chewing and grinding food



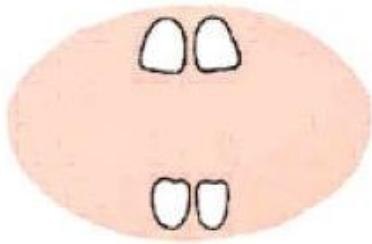
Milk teeth and the permanent teeth

Milk teeth are some features: they are smaller, have fewer tubercles and diverging roots, between which lie the beginnings of the permanent teeth. The number of roots in primary and permanent teeth are equally

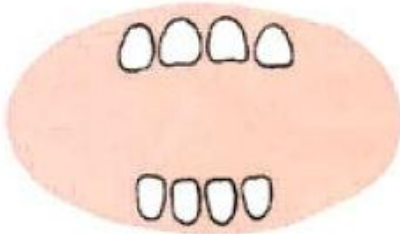


The appearance of the teeth

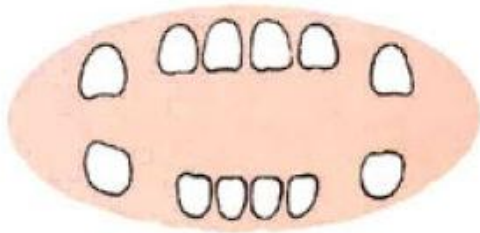
7- 9 months



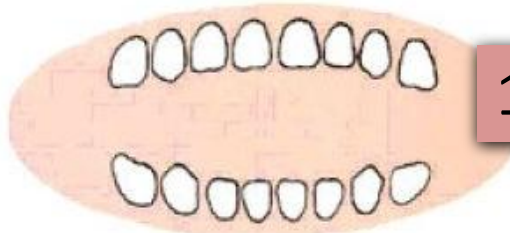
10 - 12 months



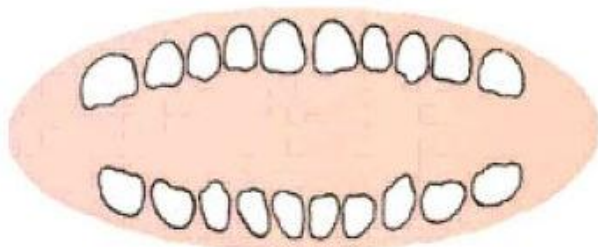
12 - 16 months



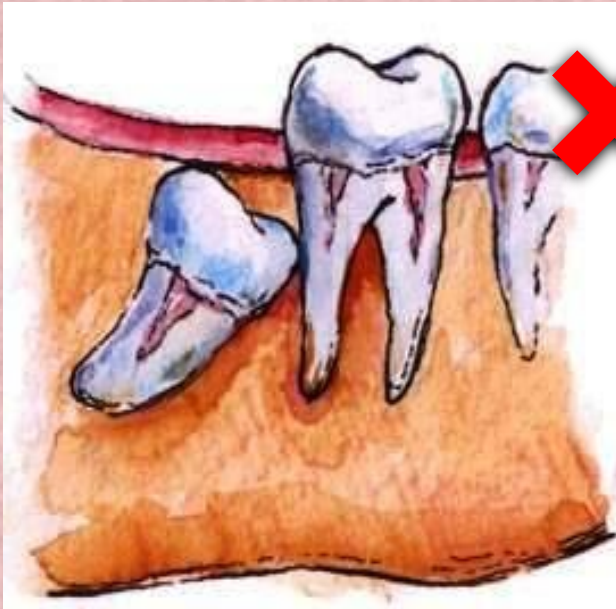
16 - 20 months



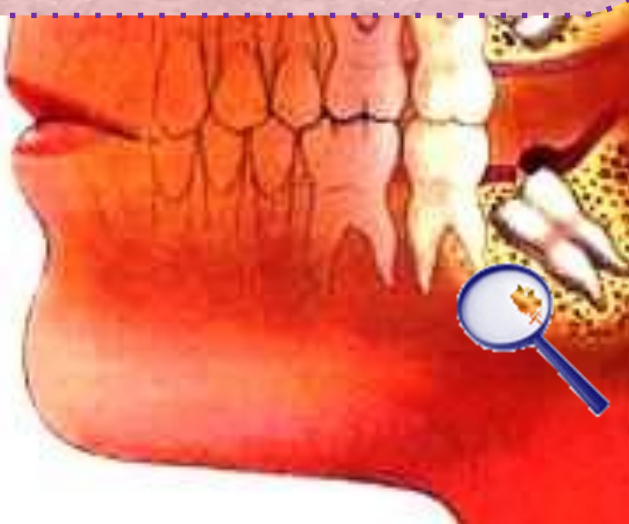24 - 30 months



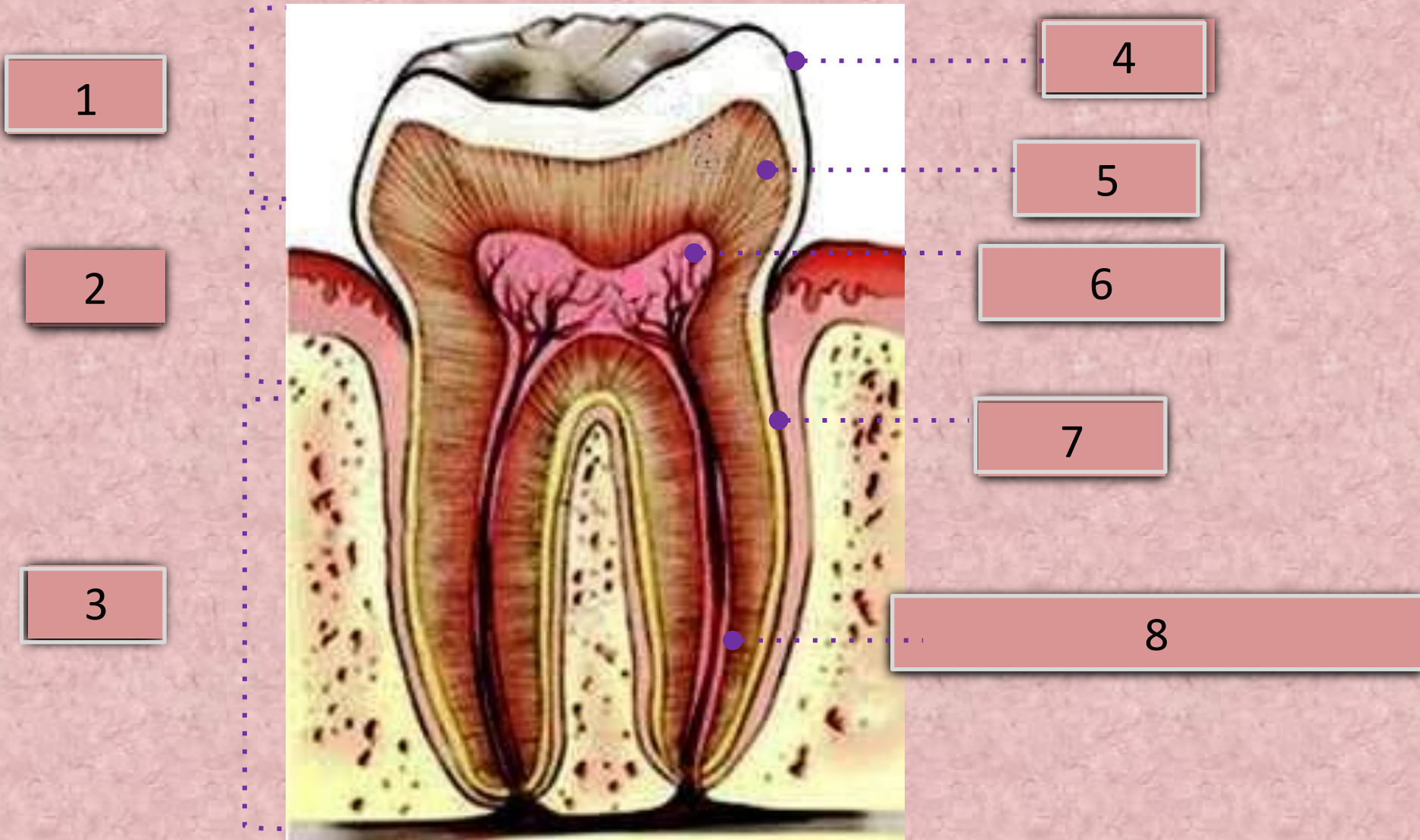
Wisdom teeth



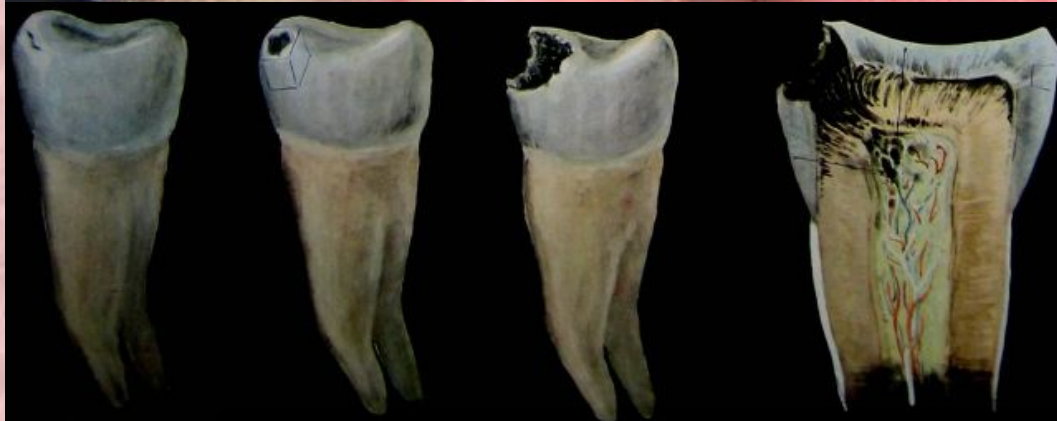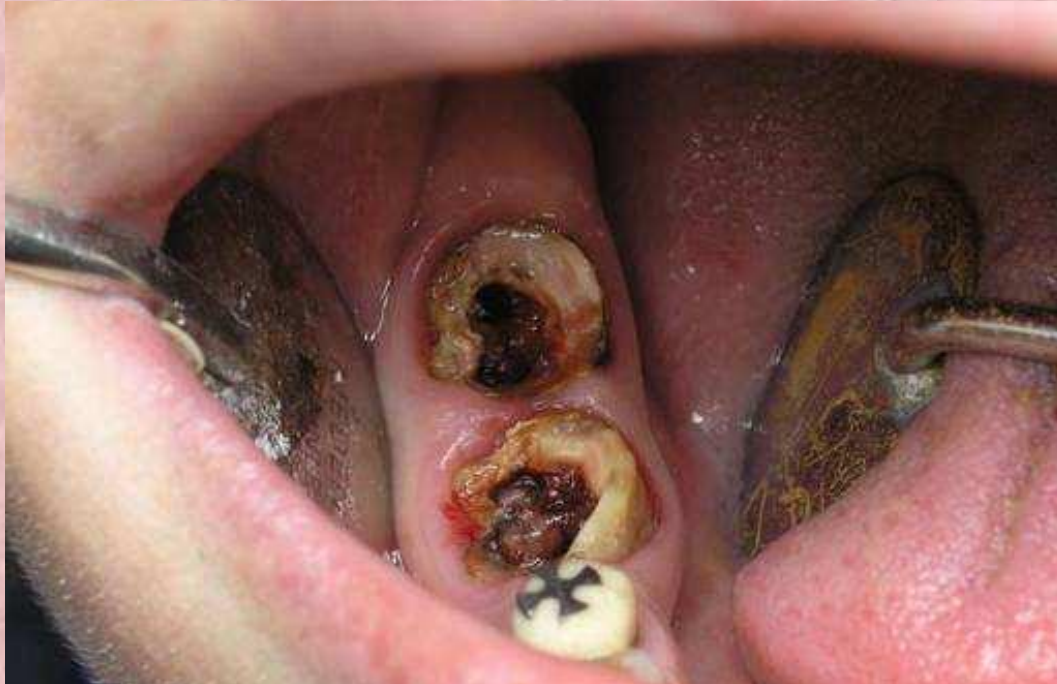When a wisdom tooth begins to grow, it is often not enough space in the current row of teeth, which can cause complications. Improper tooth eruption may be accompanied by inflammatory diseases. In the soft tissue surrounding the tooth, when the injury can penetrate the infection. The inflammation may go on deep tissue, causing periodontitis. The signs of inflammation are redness and swelling of the gums around the tooth, odor, pain.



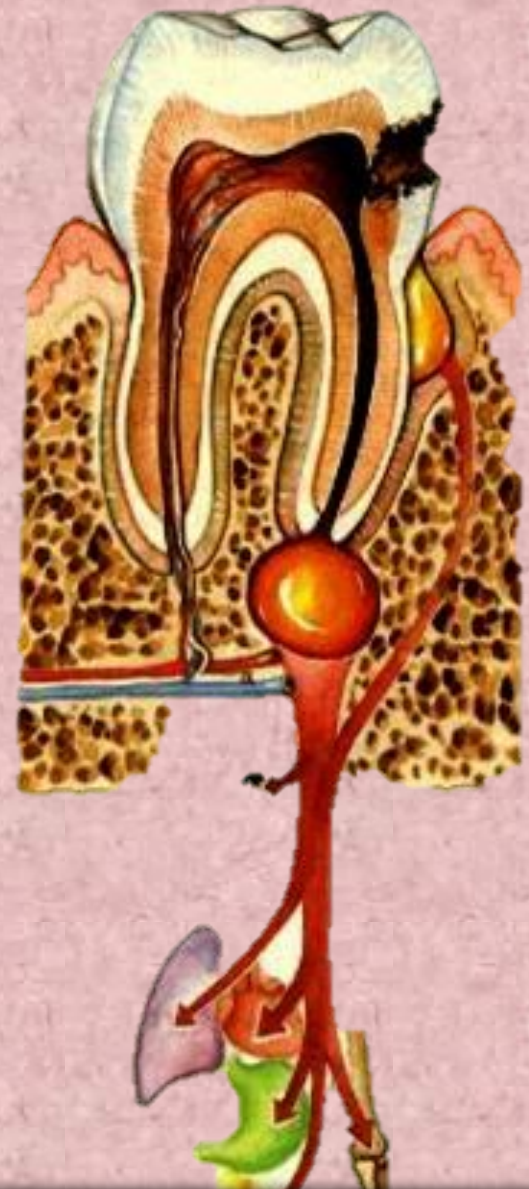The structure of the teeth



Dental disease



Stage of development of caries



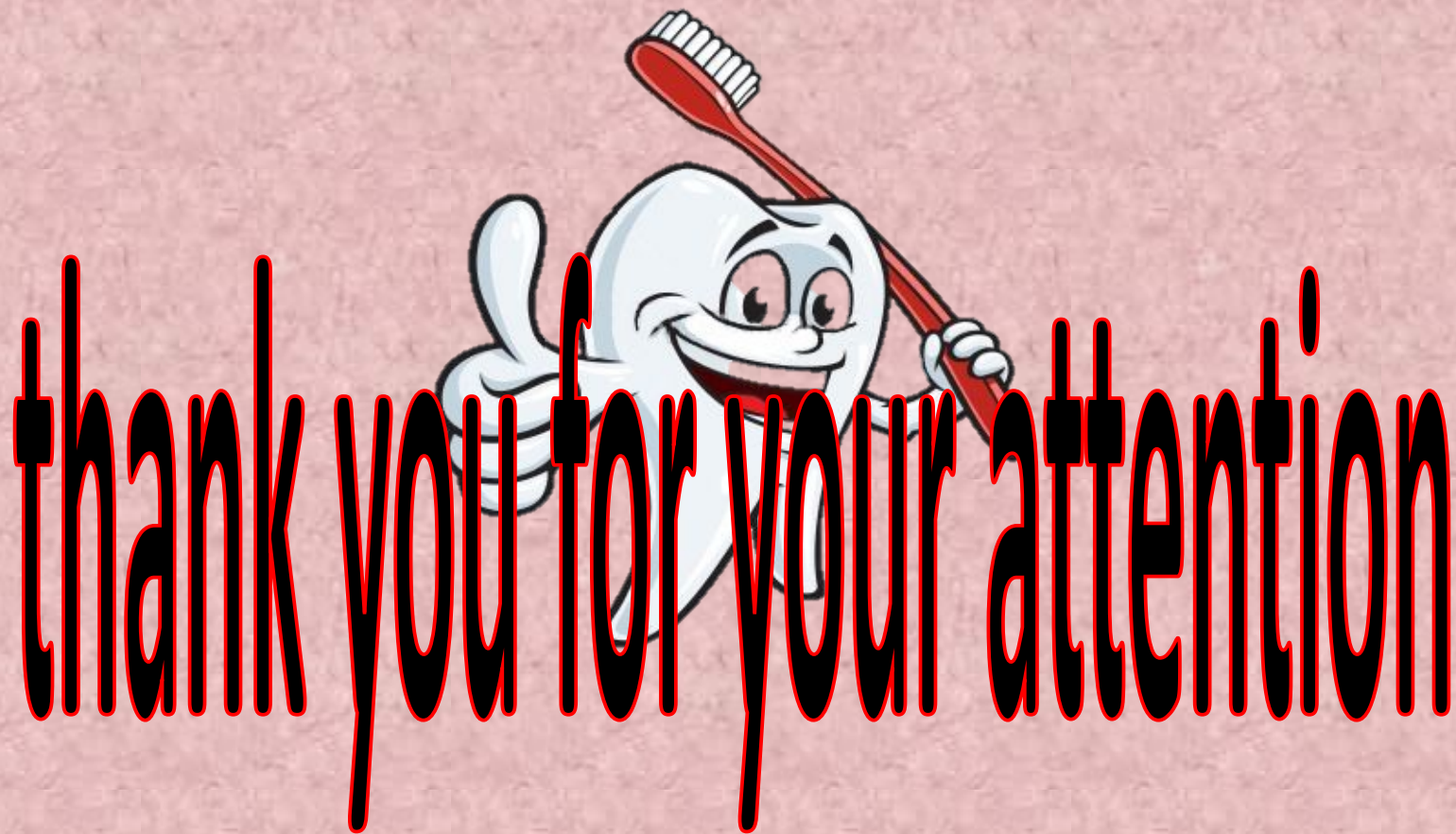Infection to internal organs

Dental hygiene

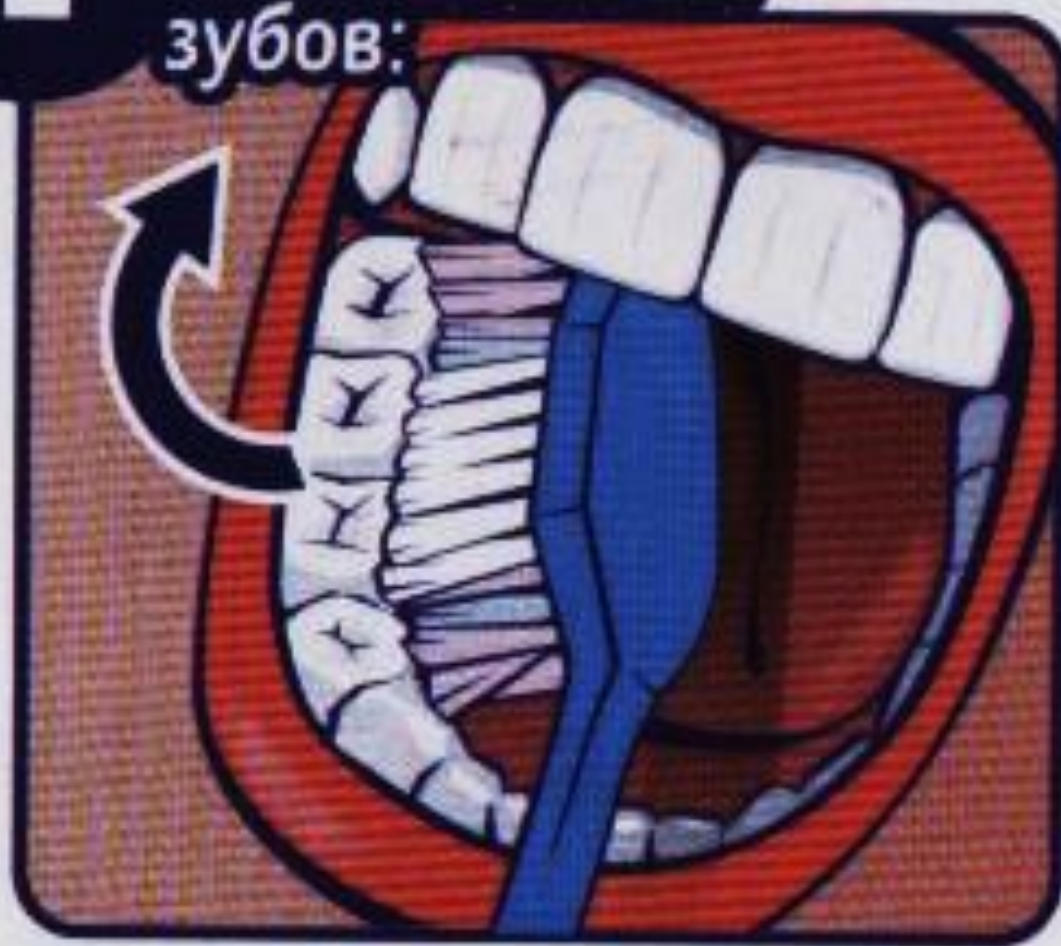

click

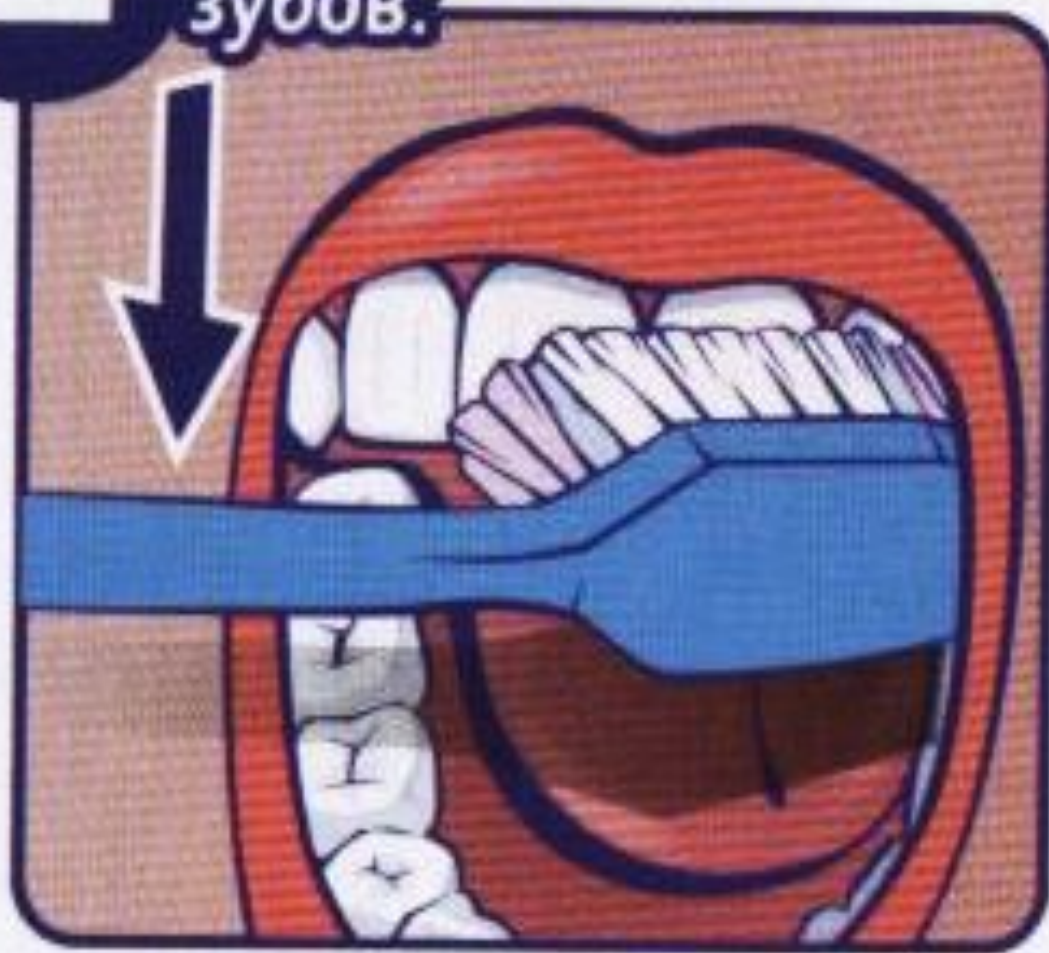
- The buccal and lingual surfaces of the teeth to be cleaned by sweeping strokes from the gums. The chewing surfaces brush and circular back and forth motions. For the proper quality of cleaning teeth, the main factor is not this effort and the thoroughness of the procedure.



1 Внутренние
поверхности
жевательных
зубов:

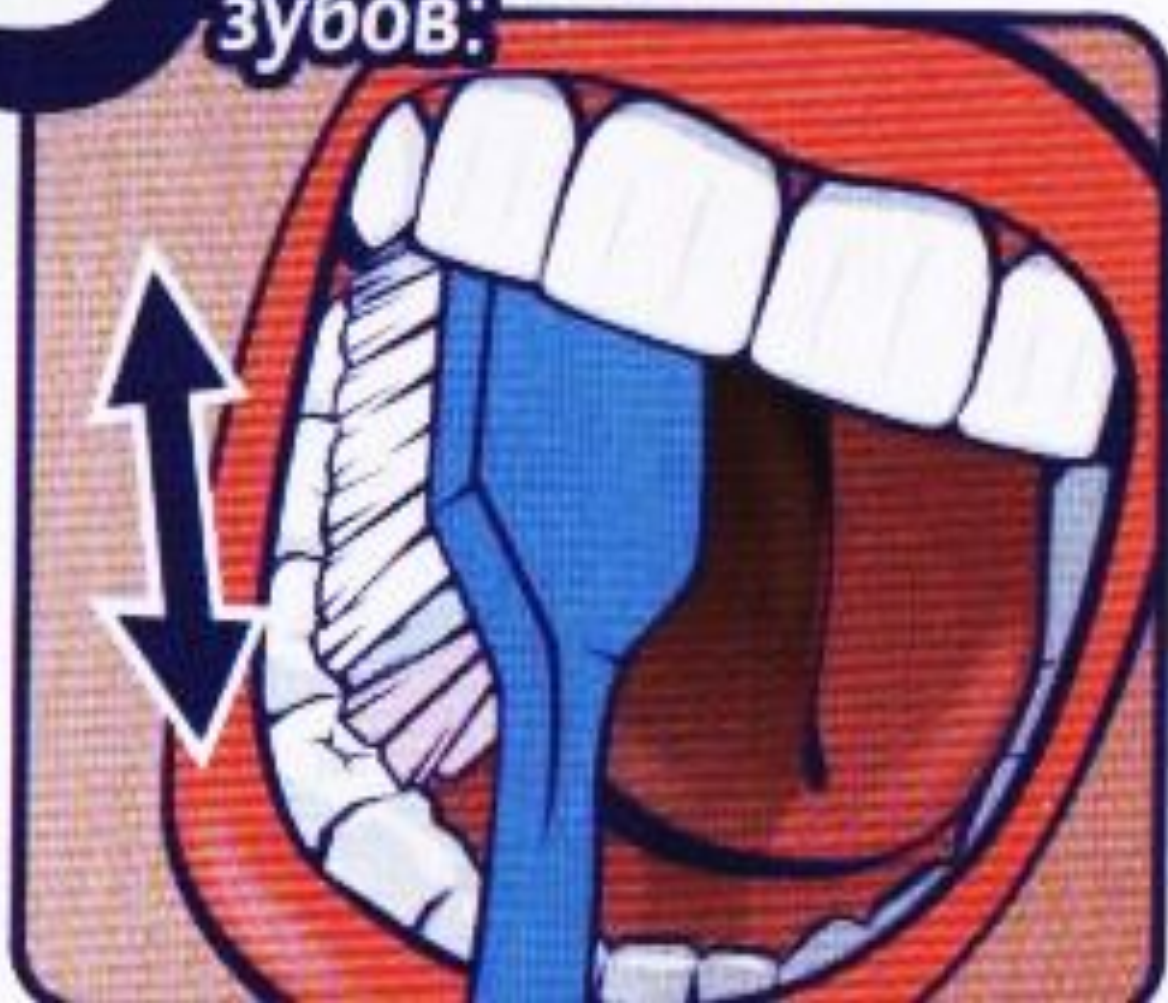

2 Наружные
поверхности
зубов:



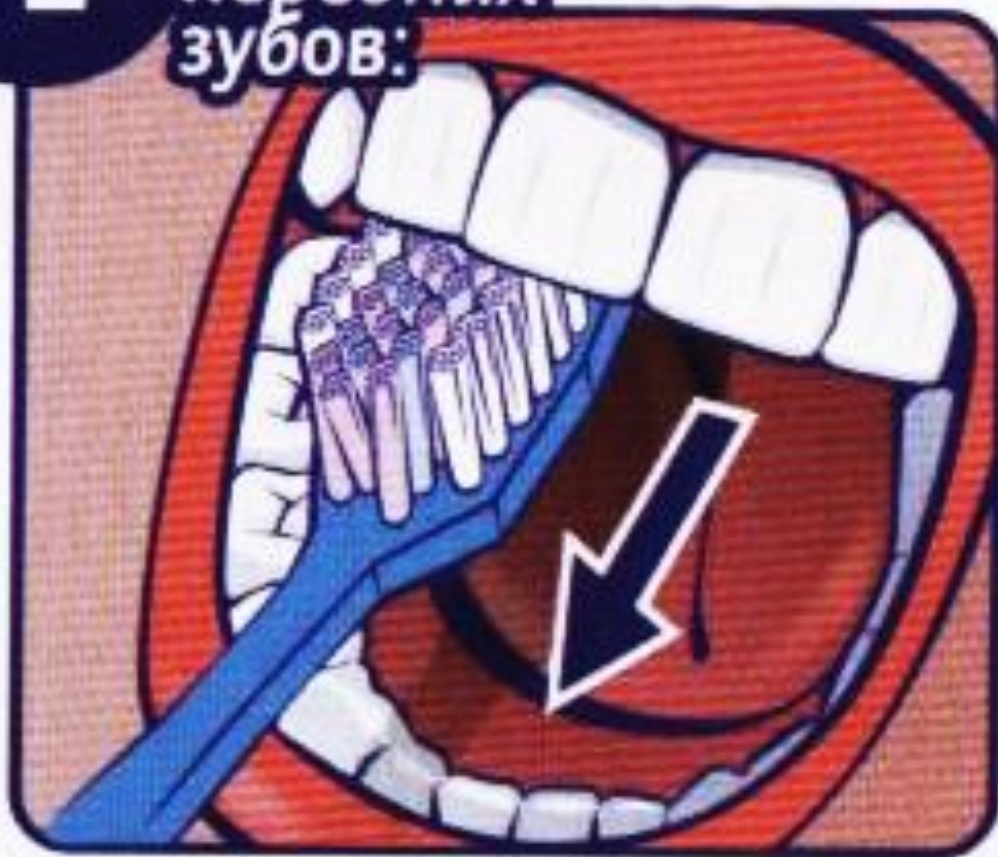3

**Жевательные
поверхности
зубов:**



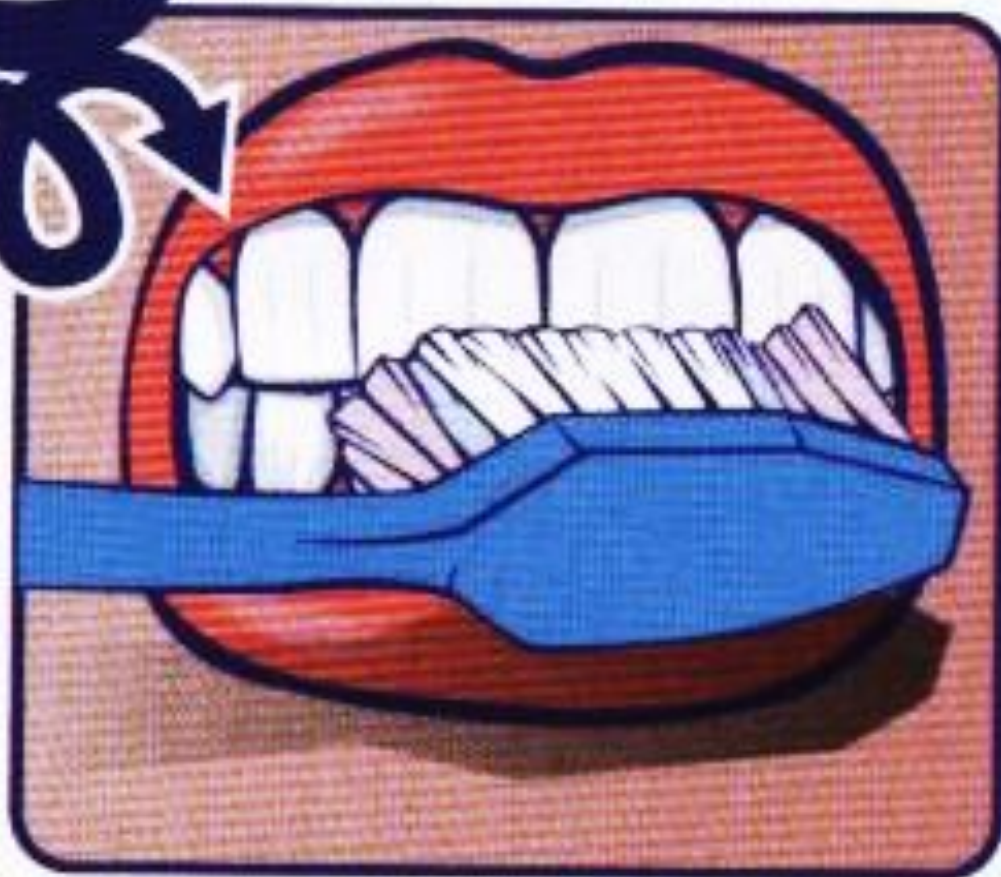4

**Внутренние
поверхности
передних
зубов:**



5

Массаж десен:



6 Чистка зубов на стадии прорезывания:

